



ORIGINAL ARTICLE

Medicine Science 2022;11(1):239-42

## Investigation of polycystic liver disease in patients with autosomal dominant polycystic kidney disease using magnetic resonance imaging

Mehtap Ilgar<sup>1</sup>, Irem Pembegul<sup>2</sup>, Serkan Unlu<sup>1</sup>

<sup>1</sup>Malatya Training and Research Hospital, Department of Radiology, Malatya, Turkey

<sup>2</sup>Malatya Turgut Ozal University, Faculty of Medicine, Department of Nephrology, Malatya, Turkey

Received 16 November 2021; Accepted 28 December 2021

Available online 02.02.01.2022 with doi: 10.5455/medscience.2021.11.378

Copyright@Author(s) - Available online at [www.medicinescience.org](http://www.medicinescience.org)

Content of this journal is licensed under a Creative Commons Attribution-NonCommercial 4.0 International License.



### Abstract

The most common hereditary kidney illness, disease of autosomal dominant polycystic kidney disease (ADPKD), is associated with numerous cysts that induce kidney size enlargement. The most common extrarenal symptom of ADPKD is liver cysts. A condition in which patients have >20 cysts in the liver is defined as polycystic liver disease (PLD). The goal of this study was to find out how often PLD was in ADPKD patients and whether there was an association between the incidence of PLD and age, sex, and clinical manifestations using magnetic resonance imaging (MRI) results. In this study, the abdominal MRI results of 32 patients with ADPKD who underwent abdominal MRI at Hospital X between January 01, 2020 and September 30, 2021 were retrospectively evaluated by 2 radiologists. Twenty-nine (90.6%) patients had a minimum 1 cyst in the liver, whereas 12 (37.5%) patients had PLD. The women had a greater rate in of PLD than males, and a statistical difference had been observed ( $p = 0.033$ ). PLD incidence was found to increase with age. The mean ages of patients with and those without PLD were 46.3 and 35.9 years, respectively, and between the foregoing mean age values, a significant difference was detected ( $p = 0.003$ ). Furthermore, there was no difference between the patients with and those without PLD in terms of the clinical indicators of ADPKD, including total kidney volume and mean rate of glomerular filtration. In conclusion, the incidence of PLD in ADPKD patients was found to be high in our study, and the presence of PLD was not associated with the clinical findings of ADPKD. For this reason, we think that it may be beneficial to perform liver imaging at the time of diagnosis of ADPKD and in their routine follow-up.

**Keywords:** Magnetic resonance imaging, disease of polycystic kidney, polycystic liver disease

### Introduction

The most frequent kind of polycystic kidney disease is the disease of autosomal dominant polycystic kidney disease (ADPKD), which is the most frequent hereditary kidney condition. It affects around one in every 500–1000 newborns [1, 2] and is marked by numerous cysts that induce kidney size enlargement. It's associated with progressive loss of kidney function, a drop-in rate of glomerular filtration (GFR), and, for most cases, disease of end-stage renal. Hypertension is a frequent side effect in ADPKD. Gross hematuria, cyst infection, chronic and acute pain, and nephrolithiasis are among the other complications that

are associated with cyst development and growth. Pancreatic and hepatic cysts, intracranial aneurysms, and heart valve lesions are all extrarenal ADPKD symptoms [3].

Genetic testing is the most sensitive diagnostic method for ADPKD. However, due to its high costs, it is not widely used [4]. Therefore, ultrasonography is the most frequently used ADPKD diagnosis method owing to its noninvasive nature and favorable cost. The number of cysts that indicate the presence of ADPKD is defined by age. In persons aged 15–39, three cysts in bilateral or unilateral kidney must be visible, in persons aged 40–59 in each kidney at least two cysts, and in persons aged > 60 in each kidney at least four cysts, according to ultrasonographic diagnostic criteria for ADPKD [5]. Although kidney size enlargement is a universal manifestation of ADPKD, it has not yet been added to the diagnostic criteria. For the radiological classification and diagnosis of ADPKD, magnetic resonance imaging (MRI) can be used follow-up of chronic disease progression of kidney, and investigation of problems such as hemorrhage or cyst infection.

\*Corresponding Author: Mehtap Ilgar, Malatya Training and Research Hospital, Department of Radiology, Malatya, Turkey  
E-mail: [mehtapilgar@gmail.com](mailto:mehtapilgar@gmail.com)

Furthermore, the gold standard for determining total kidney volume (TKV) is MRI [6].

The most prevalent extrarenal ADPKD symptom is liver cysts, which usually occur after kidney cyst development [7]. Specific mutations that induce increased differentiation, proliferation, and secretion in biliary epithelial cells have been identified in individuals with the disease of polycystic liver (PLD) inherent in ADPKD. These factors are also associated with the occurrence of cysts. The presence of 20 or more cysts in the liver is a symptom of PLD [8]. Computed tomography (CT), ultrasonography, and MRI are the tools that can be employed to detect liver cysts. MRI is the imaging modality that best characterizes liver cyst complications such as hemorrhage and infection [9]. PLD is asymptomatic in most patients, and moderate elevation in gamma glutamyl transferase enzyme can be seen in relation with liver cyst burden. In rare cases, complications such as liver decompensation, variceal hemorrhage, ascites, or encephalopathy may also occur. Furthermore, liver function tests are normal for most patients [10]. Prevalent symptoms include abdominal pain and distension and discomfort associated with hepatomegaly. Back pain, dyspnea, early satiety, and dyspepsia are among the other symptoms associated with PLD. In patients with severe PLD, albeit rare, complications including hemorrhage and cyst infection can be seen [8].

The goal of this study was to find out how common PLD was in ADPKD patients and whether PLD incidence was associated with age, gender, GFR, and TKV using MRI results.

### Materials and Methods

All patients aged 18 years and over, diagnosed with ADPKD, who underwent abdominal MRI examination at Malatya Training and Research Hospital between 01.01.2020 and 30.09.2021 were included in our study. MR images of 32 patients who met these criteria were evaluated retrospectively. Images were acquired in 3-mm thickness and coronal, sagittal, and axial planes using MR-Philips Medical System 1.5 Tesla device. Two radiologists simultaneously evaluated the images using Picture Archiving and Communication systems. Coronal, sagittal, width and depth dimensions of both kidneys were measured to calculate TKV. Thereafter, TKV values were computed using the program provided at the Mayo Clinic website [11]. On examining the patients' liver images, those found to have >20 cysts in their liver were considered as having PLD. MRI image of ADPKD patient with PLD in figure 1 and figure 2 is presented. Liver enzyme, including alkaline phosphatase, gamma glutamyl transferase, alanine aminotransferase, and aspartate aminotransferase, and bilirubin values of the patients, were retrieved from the hospital's data processing system. GFR values were also computed using the data available in the hospital's information system.

This retrospective study received approval from Malatya Turgut Özal University Clinic Ethics Committee. Protocol number is 2021/77.

### Statistical analyses

For conducting statistical analyses, Version 22 of SPSS package was employed. Patients were separated into two groups based on their age ≤40-year and >40-year groups. Additionally, groups were

formed based on GFR values—GFR ≥60 and GFR <60 groups. Chi-square and t tests were used for performing comparisons between patients with and those without PLD. A p-value of 0.05 was considered statistically significant all of the aforementioned tests which were designed as two-sided.

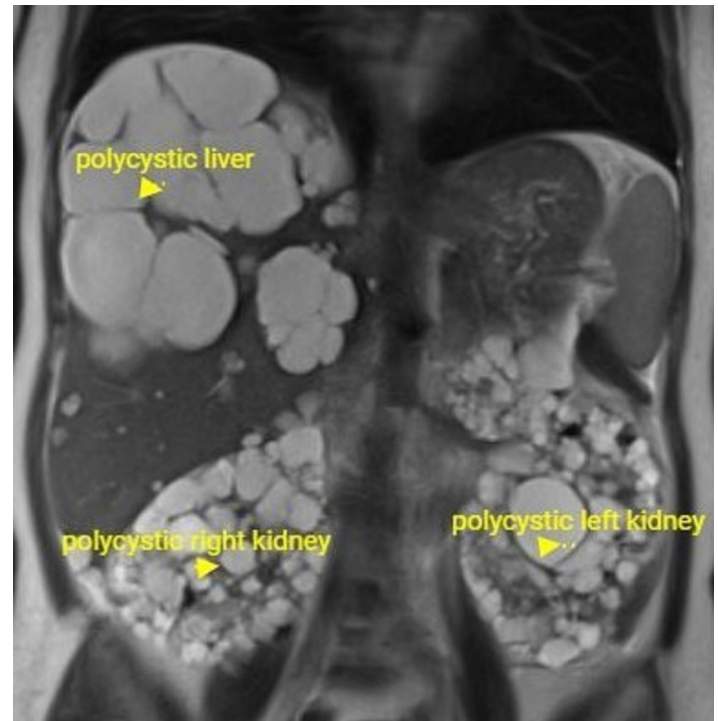


Figure 1. MRI image of ADPKD patient with PLD

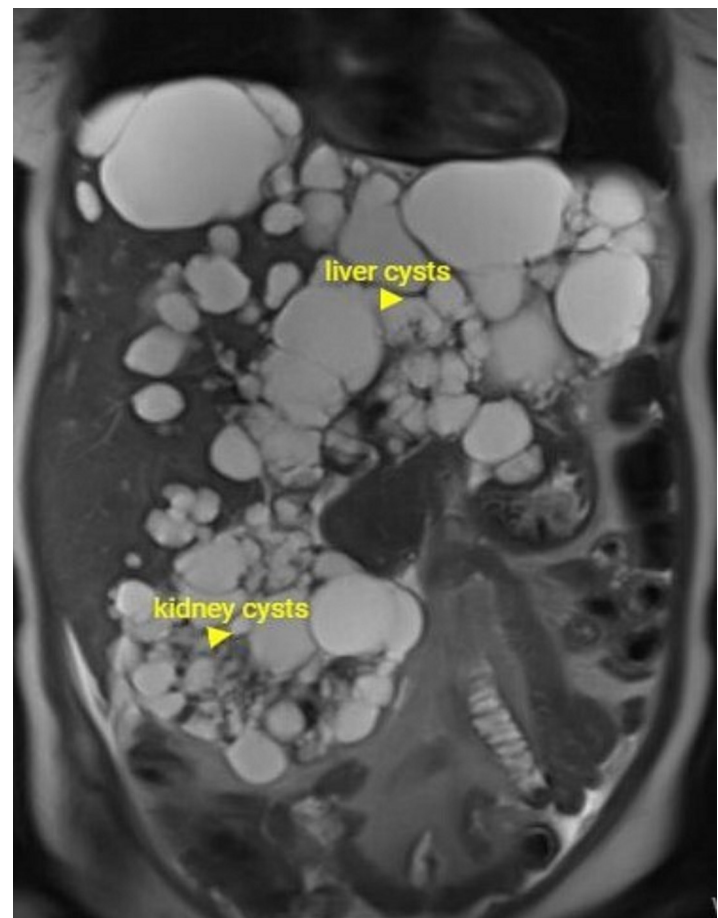


Figure 2. In the same patient, liver size increased due to cysts

## Results

Of the research participants, 19 (59.4%) were female. The ages of the participants changed from 18 to 61, and the average age was  $49.8 \pm 10.1$  years. TKV values ranged between 326.5 mL and 4498.6 mL. The mean TKV was  $1130.2 \pm 892.0$ .

There was at least 1 cyst in the liver of 29 (90.6%) patients. More than 20 liver cysts, namely PLD, were seen in 12 (37.5%) patients. Liver cyst sizes ranged between 5 and 80 mm. According to hospital reference values, the bilirubin, alkaline phosphatase, gamma glutamyl transferase, alanine aminotransferase, and aspartateamino transferase levels of all the patients were within the normal limits.

The rates of the female and the male patients with PLD were 52.6% and 15.4%, respectively. The PLD incidence was higher in the women than the males with a statistically significant difference ( $p = 0.033$ ). PLD incidence rate was seen to increase with age. The mean ages of patients with and those without PLD were respectively, 46.3 and 35.9 years; and a significant difference in the mean ages of the participants had been observed ( $p = 0.003$ ). It was seen that 17.6% of the patients aged  $< 40$  and 60% patients aged  $> 40$  had PLD, and between the age samples, a significant difference had been detected with regard to PLD incidence rate ( $p = 0.014$ ). The mean TKV values of patients with and those without PLD were 1118.7 mL and 1137.1 mL, respectively, and there was no significant difference on the base of mean TKV values ( $p = 0.956$ ). Additionally, there was no difference between patients with a GFR value of  $< 60$  and those with a GFR value of  $> 60$  ( $p = 0.225$ ) in terms of PLD incidence rate; no significant difference was observed even in terms of mean GFR values ( $p = 0.195$ ). The results are shown in the table 1.

**Table 1.** A comparison of patients with and those without PLD in terms of certain demographic and clinical features

|                 | PLD absent<br>n (%) or<br>mean $\pm$ SD | PLD present<br>n (%) or<br>mean $\pm$ SD | All patients<br>n (%) or<br>mean $\pm$ SD | p-value |
|-----------------|---|--|---|---------|
| Age             | 35.9 $\pm$ 9.7                          | 46.3 $\pm$ 7.2                           | 39.8 $\pm$ 10.1                           | 0.003   |
| $\leq 40$ years | 14(82.4)                                | 3(17.6)                                  | 17(100)                                   | 0.014   |
| $> 40$ years    | 6(40.0)                                 | 9(60.0)                                  | 15(100)                                   |         |
| Female          | 9(47.4)                                 | 10(52.6)                                 | 19(100)                                   | 0.033   |
| Male            | 11(84.6)                                | 2(15.4)                                  | 13(100)                                   |         |
| GFR $\geq 60$   | 17(68.0)                                | 8(32.0)                                  | 8(32.0)                                   | 0.225   |
| GFR $< 60$      | 3(42.9)                                 | 4(57.1)                                  | 4(57.1)                                   |         |
| GFR             | 88.8 $\pm$ 30.5                         | 74.3 $\pm$ 29.3                          | 83.3 $\pm$ 30.4                           | 0.195   |
| TKV             | 1137.1 $\pm$ 1036.6                     | 1118.7 $\pm$ 621.4                       | 1130.2 $\pm$ 892.0                        | 0.956   |

## Discussion

The liver cyst is the most prevalent extrarenal symptom of ADPKD. The incidence rate of liver cysts increases by age. The general prevalence was reported to be between 67% and 83%, whereas it reaches 95% in patients aged  $> 40$  [12, 13]. The results of the present study were consistent with the foregoing findings, and 90.6% of the patients had a minimum of one cyst in their liver. PLD is referred to the occurrence of  $> 20$  cysts in the liver. The rate of PLD incidence in patients with ADPKD was found to be 50%–60% in an autopsy and surgery series. PLD incidence increases by age, and children have low rates of incidence. The rate of incidence is 20% in patients in their 30s, whereas it rises to 75% in patients in their 70s [14-16]. Consistent with other studies, in the present study the average age of individuals with PLD was significantly higher compared to that of those without PLD, and the incidence rate was high in patients aged  $> 40$ .

In this study, the rate of PLD incidence in female patients was significantly higher than males. Similarly, in certain relevant studies, the PLD incidence was higher in women having ADPKD than men having ADPKD. It was also reported that the size and amount of the cysts were high in women. Moreover, it was suggested that this might be associated with the estrogen hormone and pregnancy, oral contraceptive use, and estrogen replacement therapy affect cyst development and growth [14, 17]. When triggered, epithelial cells of liver cyst express growth factors and host estrogen receptors, comparable to growth factor-1 of insulin-like, as well as cytokines and growth hormones that aid cyst growth [18].

TKV and GFR levels are the parameters that provide information regarding the clinical condition of ADPKD patients. There was no significant difference between ADPKD and PLD patients in our research, and those with ADPKD and without PLD in terms of mean kidney volume and mean GFR. Furthermore, there was no discernible difference between those with GFR levels of  $> 60$  and those with GFR levels of  $< 60$  in terms of PLD incidence. There was no association between the severity of liver illness and renal disease in research by Levine et al. Levine et al. suggested that this might be associated with the fact that liver cysts usually occurred in the 30s and 40s, i.e., at an older age, compared to renal cysts [19]. Everson et al. found no significant relation between renal volume and liver cyst volume in a comparison of the using CT [20]. Similarly, there was no correlation between the enlargement of liver cysts and TKV in another study. The authors suggested that liver and kidney cysts may have different growth factors [21].

Quantitative liver tests indicate preserved liver functions in most patients with PLD. Even in individuals with severe PLD, the volume of parenchymal liver is usually conserved, and the liver's protein-synthesizing ability is usually preserved. There may be a slight but substantial decrease in antipyrine clearance and first-pass eradication due to cholate shunt in individuals with severe PLD. Furthermore, the alkaline phosphatase and serum gamma glutamyl transferase levels may be increased. Bilirubin levels are generally at normal levels, but it may be elevated in cases wherein the cysts compress the biliary tract [8, 22]. In the present study, bilirubin, phosphatase, alkaline, gamma glutamyl transferase, alanine aminotransferase, and the aspartate aminotransferase levels of all the patients were within the normal limits.

The limitation of the present study was the small number of patients.

## Conclusion

In our study, the incidence of PLD in ADPKD patients was found to be high, and the presence of PLD was not associated with clinical findings. For this reason, we think that it may be beneficial to perform liver imaging at the time of diagnosis of ADPKD and in their routine follow-up.

## Conflict of interests

*The authors declare that they have no competing interests.*

## Financial Disclosure

*All authors declare no financial support.*

## Ethical approval

*This retrospective study received approval from Malatya Turgut Özal University Clinic Ethics Committee. Prothocol number is 2021/77.*

## References

- Wilson PD. Polycystic Kidney Disease. *N Engl J Med.* 2004;350:151-64.
- Zhao X, Paterson AD, Zahirieh A, et al. Molecular Diagnostics in Autosomal Dominant Polycystic Kidney Disease: Utility and Limitations. *Clin J Am Soc Nephrol.* 2008;3:146–52.
- Cornec- Le Gall E, Alam A, Perrone RD. Autosomal Dominant Polycystic Kidney Disease. *Lancet.* 2019;393:919-35.
- Gradzik M, Niemczyk M, Gołębowski M, Pączek L. Diagnostic Imaging of Autosomal Dominant Polycystic Kidney Disease. *Pol J Radiol.* 2016;81:441-53.
- Rahbari-Oskoui F, Mittal A, Mittal P, Chapman A. Renal Relevant Radiology: Radiologic Imaging in Autosomal Dominant Polycystic Kidney Disease. *Clin J Am Soc Nephrol.* 2014;9:406–15.
- Zhang W, Blumenfeld JD, Prince MR. MRI in Autosomal Dominant Polycystic Kidney Disease. *Journal of Magnetic Resonance Imaging.* 2019;50:41-51.
- Halvorson CR, Bremmer MS, Jacobs SC. Polycystic Kidney Disease: Inheritance, Pathophysiology, Prognosis, and Treatment. *International J Nephrol Renovascular Disease.* 2010;3:69–83.
- Gevers TJG, Drenth JPH. Diagnosis and Management of Polycystic Liver Disease. *Gastroenterol Hepatol.* 2013;10:101-8.
- Morgan DE, Lockhart ME, MD, Canon CL, Holcombe P, Bynon S. Polycystic Liver Disease: Multimodality Imaging for Complications and Transplant Evaluation. *Radiographics.* 2006; 26:1655-68.
- Everson GT, Taylor MRG, Doctor RB. Polycystic Disease of the Liver. *Hepatology.* 2004;40:774-82.
- Classification of Typical ADPKD Calculator Web-Based Application (:e Web-Based Application),<http://www.mayo.edu/research/documents/pkd-center-adpkd-classification/doc-20094754>.
- Nicolau C, Torra R, Bianchi L, et al. Abdominal Sonographic Study of Autosomal Dominant Polycystic Kidney Disease. *J Clin Ultrasound.* 2000;28:277-82.
- Bae KT, Zhu F, Chapman AB, et al. Magnetic Resonance Imaging Evaluation of Hepatic Cysts in Early Autosomal-Dominant Polycystic Kidney Disease: The Consortium for Radiologic Imaging Studies of Polycystic Kidney Disease Cohort. *Clin J Am Soc Nephrol.* 2006;1:64-9.
- Qian Q, Li A, King BF, et al. Clinical Profile of Autosomal Dominant Polycystic Liver Disease. *Hepatology.* 2003;37:164-71.
- Milljtinovic J, Fialkow PJ, Rudd TG, Agodoa LY, et al. Liver Cysts in Patients with Autosomal Dominant Polycystic Kidney Disease. *Am J Med.* 1980;88:741-4.
- Gabow PA, Johnson AM, Kaehny WD, et al. Risk Factors for the Development of Hepatic Cysts in Autosomal Dominant Polycystic Kidney Disease. *Hepatology.* 1990;11:1033-7.
- Chauveau D, Fakhouri F, Grunfeld JP. Liver Involvement in Autosomal-Dominant Polycystic Kidney Disease: Therapeutic Dilemma. *J Am Soc Nephrol.* 2000;11:1767–75.
- Onori P, Franchitto A, Mancinelli R, et al. Polycystic liver diseases. *Dig Liver Dis.* 2010;42:261–71.
- Levine E, Cook L, Grantham JJ. Liver Cysts in Autosomal Dominant Polycystic Kidney Disease: Clinical and Computed Tomographic Study. *AJR.* 1985;145:229-33.
- Everson GT, Scherzinger A, Berger-Leff N, et al. Polycystic Liver Disease: Quantitation of Parenchymal and Cyst Volumes from Computed Tomography Images and Clinical Correlates of Hepatic Cysts. *Hepatology.* 1988;8:1627–34.
- Matsuura R, Honda K, Hamasaki Y, et al The Longitudinal Study of Liver Cysts in Patients with Autosomal Dominant Polycystic Kidney Disease and Polycystic Liver Disease. *Kidney International Reports.* 2017;2:60–5.
- Everson GT. Hepatic Cysts in Autosomal Dominant Polycystic Kidney Disease. *Am J Kidney Dis.* 1993;22:520-25.